

OPEN

# Use of Three-dimensional Printing in Orthopaedic Surgical Planning

Marcelo Galvez, MD  
 Takeshi Asahi  
 Alejandro Baar, MD  
 Giovanni Carcuro, MD  
 Natalio Cuchacovich, MD  
 Jorge A. Fuentes, BS  
 Rodrigo Mardones, MD  
 Carlos E. Montoya, BS  
 Roberto Negrin, MD  
 Felipe Otayza, MD  
 Gonzalo M. Rojas, BS  
 Andrés Chahin, MD

From the Department of Radiology (Dr. Galvez), the Medical Biomodeling Laboratory, Department of Radiology (Mr. Asahi, Mr. Fuentes, Mr. Montoya, and Mr. Rojas), the Department of Traumatology (Dr. Baar, Dr. Carcuro, Dr. Cuchacovich, Dr. Mardones, and Dr. Negrin), the Advanced Epilepsy Center (Dr. Otayza), and the Spine Center, Department of Traumatology (Dr. Chahin), Santiago, Chile.

Correspondence to Marcelo Galvez: [mgalvez@clinicalascondes.cl](mailto:mgalvez@clinicalascondes.cl)

*JAAOS Glob Res Rev* 2018;2:e071

DOI: 10.5435/  
 JAAOSGlobal-D-17-00071

Copyright © 2018 The Authors. Published by Wolters Kluwer Health, Inc. on behalf of the American Academy of Orthopaedic Surgeons. This is an open-access article distributed under the terms of the Creative Commons Attribution-Non Commercial-No Derivatives License 4.0 (CCBY-NC-ND), where it is permissible to download and share the work provided it is properly cited. The work cannot be changed in any way or used commercially without permission from the journal.

## Abstract

**Background:** Three-dimensional (3D) printing is a technique based on overlapping layers of a material (eg, plastic, clay, and metal). The widespread implementation of 3D printers has resulted in a notable increase in use. Fields such as construction, engineering, and medicine benefit from this technique.

**Aim:** The use of 3D printed scale models permits better surgical planning and results.

**Methods:** The models were created based on CT images of seven patients (age range, 5 to 61 years) with different pathologies who were candidates for surgery.

**Results:** Surgical time decreased as a result of detailed surgical planning with printed models. This technique also was associated with a decrease in bleeding, a reduction in the amount of anesthesia required, and greater precision. In some patients, a change in surgical strategy was noted, thus allowing for a reduction in the number of surgeries and the aggressiveness of surgery. Finally, the preoperative practice (virtual and physical osteotomies using cutting tools) that was performed in two cases allowed the surgeon to evaluate the different approach alternatives and establish the best strategy.

**Conclusions:** The use of 3D-printed anatomic models has improved surgical planning, especially for patients in whom the conventional techniques are insufficient for establishing a proper strategy. The extra information provided by 3D-printed models can lead to a better intervention strategy, which is beneficial for patients because it decreases the risks, procedure times, and recovery times.

Three-dimensional (3D) printing is a technique involving overlapping of layers to create an object based on a previously generated design using specialized software. The use of 3D printing was first mentioned by Hull in 1980 with the stereo-

lithography concept.<sup>1</sup> Rapid prototyping, which is the creation of physical models based on computer data, has been used widely in industry.<sup>2</sup> In a document published by PwC,<sup>3</sup> it is noted that two thirds of the top 100 manufacturing companies in

the world use 3D printers. Of the companies that use this technology, 30% do so on an experimental basis, 25% only for prototypes, 10% for prototypes, and experimentally, 3% for models that cannot be created by traditional methods, and just 0.9% for the final production of their products.

Because of technological advances, 3D printing technology has recently gained ground in the field of medicine with its potential benefits. 3D printers are becoming necessary in medical applications, including surgical planning, the creation of implants and prostheses, and medical education. In the dental field, 3D printing is commonplace worldwide and is essential for complex treatments.<sup>4,5</sup>

One of the most important aspects of applying 3D technology in medicine is the personalized production of objects associated not only with the requirements of the patients but with those of the surgeons.

In addition to the progress that has been made in the visualization of images, surgical planning has improved with the use of 3D printing by providing more information about the anatomy of the patient and a better understanding by the surgical team.<sup>6</sup> For complex cases in which the information provided by conventional procedures is insufficient, 3D printed models have the advantage of replicating different organs and structures, which has generated great interest in many different specialties with regard to surgical planning.<sup>7</sup> Printed models

are based on computer models that, in turn, can be used for surgical planning via creation of simulation scenarios. Seven clinical cases are presented below in which 3D printed models were created based on patients' CT images. The printed models were validated by the radiologists and the medical teams in charge of each clinical case.

## Methods

### Segmentation and Meshes

CT images (1.0 mm slice thickness, 512 × 512 matrix size, voxel size 0.6, B30s) were obtained using a GE Optima CT660 scanner (General Electric) and Siemens SOMATOM Definition AS scanner (Siemens). The images were processed using ITK-SNAP v3.4 software<sup>8</sup> ([www.itksnap.org](http://www.itksnap.org)) in which segmentation was performed using a region-growing algorithm. Softening, reduction in the number of polygons (decimation), and visualization of the mesh were done using MeshLab (Visual Computing Lab).<sup>9</sup>

The meshes were printed using acrylonitrile butadiene styrene plastic, Fortus 250MC 3D printer (3D Systems), and Insight and Control Center software (3D Systems). These printed pieces, which were modified (in some cases) using Dremel multi-purpose tools (Dremel), allow the surgeon to physically simulate the surgical procedure. In some cases,

the created meshes were also computationally modified, creating surgical simulation scenarios using Autodesk 3ds Max.

## Patients

Four female patients and three male patients (age range, 5 to 61 years) with different pathologies were included in the study. Each patient signed a written informed consent form. All patients had an adequate or excellent postoperative evolution.

### Patient A

Surgery type: cervical.

Date of surgery (patient sex, age)

March 24, 2015 (male, 24 years).

Preoperative diagnosis: patient with Down syndrome, C1-C2 instability, and foramen magnum stenosis, with bulbo-medullary compression and signs of myelomalacia (Figure 1, A).

Surgery: Occipito-temporal decompression and craniocervical fixation (C0-C2).

Previous judgment: the patient visited the emergency department because of cervical pain. Radiographs showed C1-C2 instability. MRI and CT revealed a C1-C2 subluxation with clear instability of the same segment resulting in notable narrowing of the foramen magnum, which became even more evident on MRI given the presence of signs of myelomalacia.

Mr. Baar or an immediate family member is a member of a speakers' bureau or has made paid presentations on behalf of Orthofix; serves as a paid consultant to Orthofix; and serves as a board member, owner, officer, or committee member of Revista Chilena de Ortopedia y Traumatología and the Limb Lengthening and Reconstruction Committee of the Chilean Orthopaedic Society. Mr. Carcuro or an immediate family member is a member of a speakers' bureau or has made paid presentations on behalf of Arthrex. Mr. Cuchacovich or an immediate family member has received nonincome support (such as equipment or services), commercially derived honoraria, or other non-research-related funding (such as paid travel) from Orthofix. Mr. Mardones or an immediate family member is a member of a speakers' bureau or has made paid presentations on behalf of Smith & Nephew; has stock or stock options held in BiosCell and BiotecCel; and serves as a board member, owner, officer, or committee member of the *American Journal of Sport Medicine*, *Arthroscopy*, *Clinical Orthopaedics and Related Research*, the International Society of Hip Arthroscopy, and Revista Chilena de Ortopedia y Traumatología. Mr. Negrin or an immediate family member is a member of a speakers' bureau or has made paid presentations on behalf of Zimmer Biomet and Smith & Nephew; has received research or institutional support from Smith & Nephew; and has received nonincome support (such as equipment or services), commercially derived honoraria, or other non-research-related funding (such as paid travel) from Zimmer Biomet. None of the following authors or any immediate family member has received anything of value from or has stock or stock options held in a commercial company or institution related directly or indirectly to the subject of this article: Mr. Galvez, Mr. Asahi, Mr. Fuentes, Mr. Montoya, Mr. Otayza, Mr. Rojas, and Mr. Chahin.

Figure 1



**A**, Sagittal CT scan of the cervical spine of patient A demonstrating C1-C2 instability and stenosis of the foramen magnum, with medullary (bulbo-medullary) compression. Three-dimensional virtual representation (**B**) and three-dimensional printed model (**C**) of the affected vertebrae.

It was decided to perform posterior cervical decompression and craniocervical fixation.

**Surgery details:** general anesthesia was used and motor and sensory potentials were monitored. A midline incision was created and the median raphe was opened. The C1-C4 posterior arches and occiput were exposed. Intraoperative ultrasonography revealed compression in the bulbo-medullary region. Decompression of the C1 posterior arch was performed using a high-speed motor, and then, the epidural adhesions in the occipito-cervical region were removed. Intraoperative control ultrasonography showed adequate visualization of the posterior bulbo-medullary cistern. There was no alteration in the motor and sensory potentials during this phase of intervention.

C1-C2 instability was reduced, and it was fixed using osteosynthesis elements from the skull to C2 using plates, screws in the skull, and claw type hooks sublaminar to the C2 lamina.

**3D utility:** once the basic examinations were done, A resection of

the C1 arch and decompression of the foramen magnum were planned. The surgeons believed that resection would be necessary through the anterior pathway of the os odontoideum. The approach was modified after review of the 3D printed model, and only the C1 arch would be decompressed without touching the foramen magnum (Figure 1, B and C). Thus, the anterior pathway was avoided, and it was presumed that the release and stabilization would be adequate. In short, through the use of the model, the surgeons were able to avoid opening the foramen magnum to create a transoral anterior pathway to resect the os odontoideum.

#### Patient B

**Surgery type:** skull.

**Date of surgery (patient sex, age):** April 14, 2015 (male, 4 years).

**Preoperative diagnosis:** complex multiple-suture nonsyndromic craniosynostosis (Figure 2, A). This patient presented with left posterior plagiocephaly in addition

to scaphocephaly associated with a secondary deformity due to a ventricular shunt valve was inserted when the patient was a newborn. The shunt caused an asymmetrical turricephalic skull with a curved bone malformation in the posterior medial line.

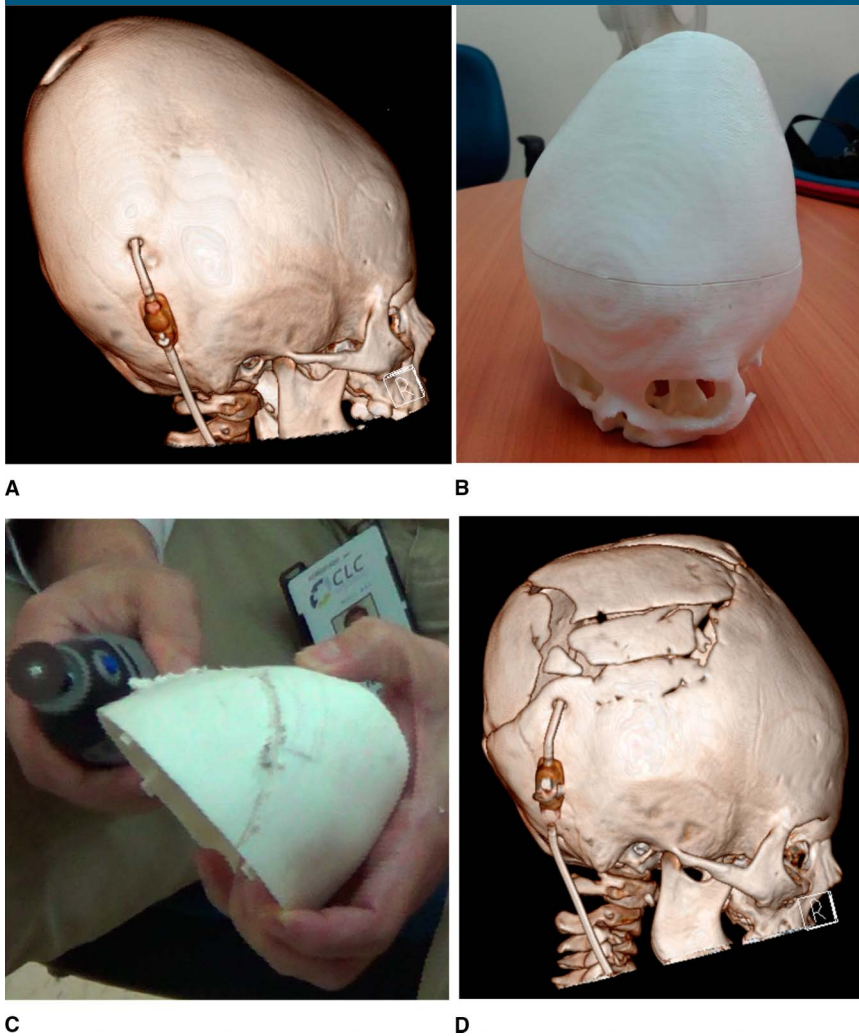
**Surgery:** cranioplasty with cranial remodeling using an autograft, remodeling of the fronto-orbital bar.

**Previous judgment:** patient with an ossified asymmetrical skull requiring extensive cranial remodeling.

**Surgery details:** satisfactory cranial remodeling.

**3D use:** the use of 3D printing allowed the surgeon to plan the osteotomies and remodeling of the skull. The printed model allowed the surgeon to visualize the complex zones of the skull and to preoperatively plan and simulate the surgery (Figure 2, B and C). Thus time was saved during surgery (it is difficult to quantify the amount of time because it was not a standard surgery; however, the surgeon estimated that approximately an hour less time was needed),

Figure 2



**A**, Preoperative CT reconstruction of the skull created with a picture archiving and communication system (PACS) using CT images of the craniosynostosis in patient B. **B**, Preoperative photograph showing the 3D printed model of the skull. **C**, Photograph showing the surgeon making incisions on the plastic model of the skull. **D**, Preoperative CT reconstruction of the skull created with PACS.

because of the strategy that was adopted (Figure 2, D). This surgery lasted approximately 4 to 5 hours. A 20% reduction in surgical time is important given the patient's age and resulted in a shorter amount of time under anesthesia, less bleeding, and a lower risk of infection (an important factor given the long duration of the surgery) due to thorough preoperative planning.

### Patient C

Surgery type: hip.

Date of surgery (patient sex, age):  
April 14, 2015 (female, 24 years).

Preoperative diagnosis: patient with Dyggve-Melchior-Clausen syndrome (see Figure, Supplemental Digital Content 1A, <http://links.lww.com/JG9/A7>), with slight mental retardation, bilateral hip dysplasia, and short

stature. Background of two siblings with the same pathology. Patient consultation for right coxalgia symptoms, exacerbation 7 years ago, the patient is able to walk without claudication, and has no need for crutches to date. The condition was refractory to medical treatment, physical therapy, and hip infiltrations. A pediatric neurologic-orthopaedic team made a joint evaluation and proposed a total arthroplasty of the right hip.

Surgery: total arthroplasty of the right hip.

Previous judgment: The patient has symptoms of progressive coxalgia secondary to permanent bone dysplasia that limits walking. A total arthroscopy of the right hip is indicated.

Surgery details: A minimally invasive posterior approach was used, and T-capsulotomy was performed. Dislocation of the hip revealed an aspheric and flattened head, which indicates degenerative compromise.

To prepare the acetabular component, the labral and residual synovial tissue were resected. A number 40 tantalum acetabular cotyle (cup) is inserted, which is fixed with three 6.5-mm screws, 25, 20, and 40 mm long. The femoral component was prepared and the hip was reduced. The direction of the components was verified, and the definitive components were left in place with a Smith and Nephew oxinium head. Capsulorrhaphy was performed and the rotators were reinserted using transosseous sutures.

3D utility: Because of the underlying disease, several complexities were encountered during surgery: first is the alteration of the anatomic references of her acetabular component, second is the reduced size of her hip, and finally, the lack and



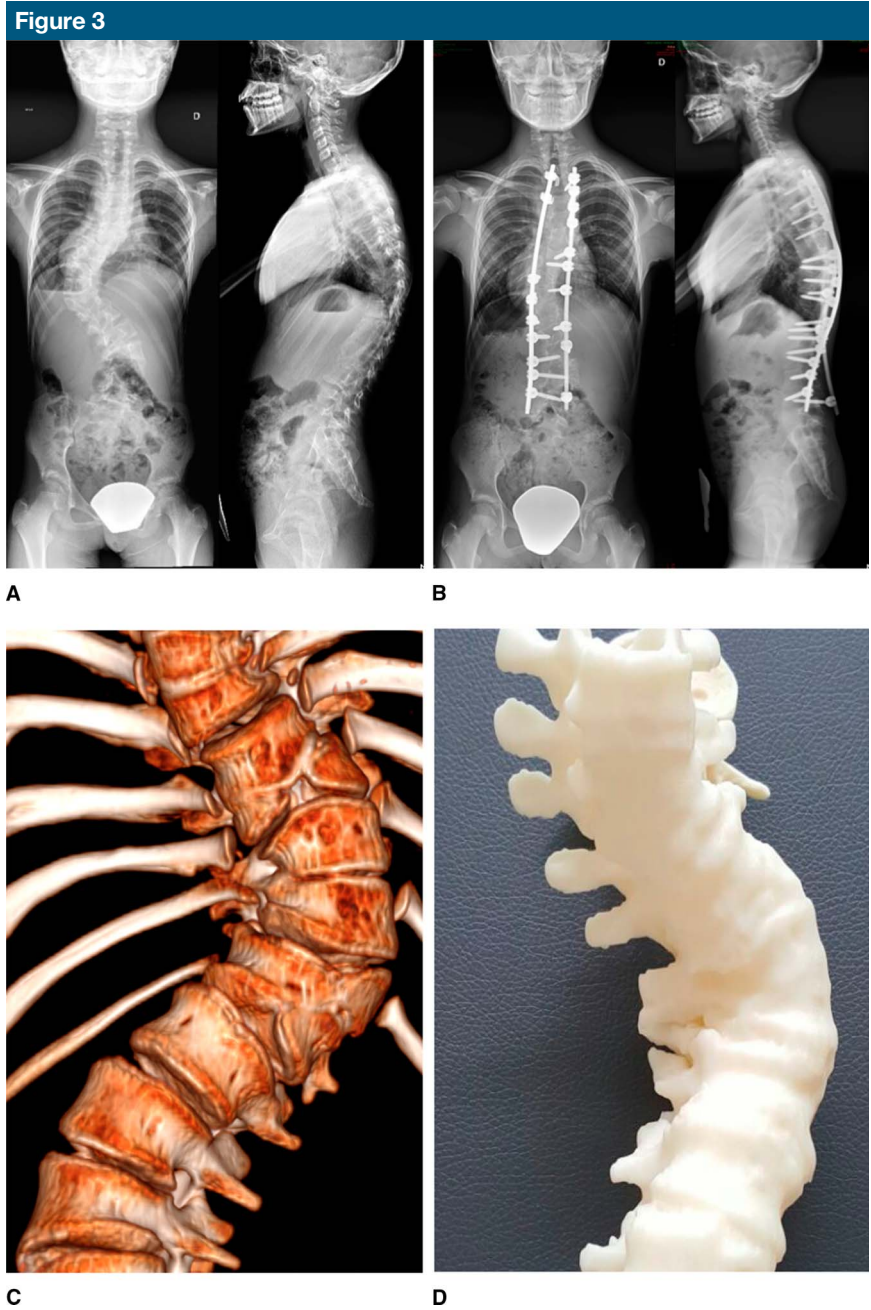
spatial alteration of the bone stock required to position the acetabulum. Her first surgery, performed several years ago, was long and complex because it required an extensive approach to enable the surgeon to see all the anatomic details and find the best bone quality and space to position the acetabulum. The 3D printed model (see Figure, Supplemental Digital Content 1B, <http://links.lww.com/JG9/A7>) was an excellent help that elucidated the quality of the bone stock, morphology, and the best bone location of the acetabular component. In addition, the model provided the exact measurement of the component and a pre-operative tridimensional vision of its position. The virtual and 3D models (see Figure, Supplemental Digital Content 1B, <http://links.lww.com/JG9/A7>) coincided perfectly with the intraoperative findings. The need for a more extensive approach was decreased, and the surgical time was dramatically reduced (4 hours in the previously operated hip without a model versus 1 hour and 30 minutes with a 3D model). The use of the model facilitated component placement (see Figure, Supplemental Digital Content 1C, <http://links.lww.com/JG9/A7>) and the patient had less discomfort during postoperative management and rehabilitation because a more conventional approach was performed.

**Patient D**

Surgery type: scoliosis.  
 Date of surgery (patient sex, age):  
 October 5, 2015 (female, 12 years).  
 Preoperative diagnosis: tethered spinal cord–scoliosis.  
 Surgery: section of the filum terminale.

Previous judgment: patient carrier of vertebral defects, anal atresia, cardiac defects, tracheoesophageal fistula, renal anomalies, and limb abnormalities syndrome associated with congenital scoliosis (Figure 3, A and C), managed

with a corset from 4 months old to date (12 years old). Management of scoliosis with instrumentation was indicated because of the progression of the malformation. During the same procedure, the lipoma of the



AP and lateral radiographs of the spine in patient D before (A) and after (B) surgical treatment for scoliosis. C, CT reconstruction of the spine created with a picture archiving and communication system from CT images. D, Photograph of the three-dimensional–printed model of the spine.

filum terminale was managed with release of the tethered spinal cord.

**Surgery details:** a durotomy was performed at L3-L4 and the lipoma of the filum terminale was sectioned, observing the immediate retraction of the same. The dura mater was closed, and the spine was exposed from T2-L3 for management of scoliosis. Pedicle screws and laminar hooks were placed. A Ponte osteotomy was performed on the apex per the preoperative plan. Premolded rods were placed, achieving translational correction and derotation (Figure 3, B).

**3D utility:** the 3D model (Figure 3, D) permitted a better understanding of the anatomy altered by the patient's base pathology. During the preoperative phase, the virtual simulation was performed on the areas where the osteotomies would be performed. A printed model was taken into the operating room, and this helped the surgical team determine the proper orientation of the pedicles, their size, and select the implant to be used. The latter resulted in a notable decrease in the amount of work that had to be done and less irradiation (decreased use of radiography) during the surgery.

### Patient E

**Surgery type:** foot.

**Date of surgery (patient sex, age):** November 15, 2015 (female, 15 years).

**Preoperative diagnosis:** Proteus syndrome resulting in malformation of the left foot and claw toes.

**Surgery:** correction of claw toes—resection of the fourth metatarsal dorsum and plantar exostosis—removal of the osteosynthesis material.

**Previous judgment:** patient presented with malformation of the left foot (Figure 4, A) and notable plantar exostosis that caused painful plantar ulcers. Furthermore, toward the medial section of the foot, there is protrusion of the symptomatic osteosynthesis material. Finally, the toes present a rigid claw malformation, which makes the use of shoes very difficult. Corrections of the aforementioned alterations are performed.

**Surgery details:** through a transverse plantar approach, a large exostosis is identified at the head of the second and third metatarsal, which is completely resected. The procedure continued, approaching the dorsum of the foot between the third and fourth metatarsal, and the exostosis was resected without any difficulty. Using the same incision, the medial metatarsophalangeal capsule of the fifth toe is released, and the toe was aligned without any problem. The procedure continues focused on the hindfoot. The bone layer was approached through the lateral scar. Osteonecrosis of the distal area of the calcaneus was verified. The area of the exostosis to be resected is outlined using radiographs. Finally, the previously osteotomized toes are fixed into place. Retrograde Kirschner needles are used to fix the toes to the metatarsal head. Good alignment of the forefoot was achieved.

**3D utility:** the use of the model printed in plastic (Figure 4, B) and the virtual model (Figure 4, C), with different cuts of the foot, made it possible to plan more precisely the bone resection of the calcaneus to calculate the amount of pressure in the load area. The benefit of these techniques resulted in a less invasive approach during

surgery. The procedure was able to be practiced before the actual surgery. The most important benefits were the decrease in surgical time because of better surgical planning and consequently fewer incisions for the resection. We narrowed down the bone cuts to improve the percentage of loads that were desired. Without the 3D printed model, the bone resection would have probably included additional cuts, which would have caused longer surgery and recovery times in addition to a second surgery, if necessary. The decreased use of radiographs is another important factor to consider in the benefits of using virtual and plastic models because they allow better mapping of the area.

### Patient F

**Surgery type:** knee.

**Date of surgery (patient sex, age):** November 5, 2015 (male, 29 years).

**Preoperative diagnosis:** patient with previous reconstruction of the anterior cruciate ligament in the right knee in 2009. Asymptomatic until October 15, 2015, when instability and failure in forced torque occurred again. MRI reveals a lesion in the graft and medial meniscus. The patient was admitted for elective surgery to reconstruct the anterior cruciate ligament and repair the medial meniscus.

**Surgery:** reconstruction of the anterior cruciate ligament in the knee joint.

**Previous judgment:** patient with graft failure and medial meniscus lesion with previous anterior tunneling (see Figure, Supplemental Digital Content 2A, <http://links.lww.com/JG9/A8>). Surgery is scheduled to reconstruct the

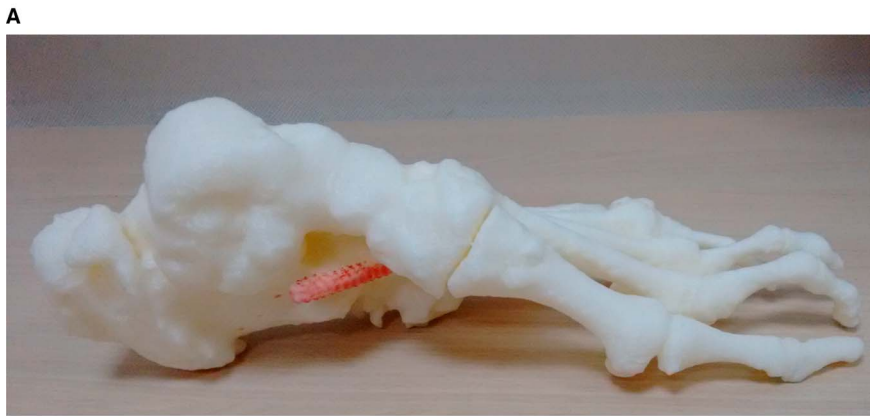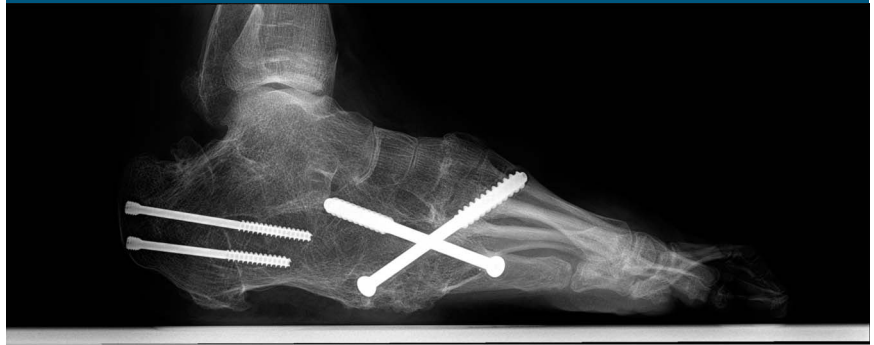anterior cruciate ligament and repair the meniscus.

Surgery details: reducible bucket-handle lesion, from the posterior horn to the middle segment of the medial meniscus. Tissue appears healthy and no pathological findings in the joint surfaces. Nonviable graft present in the intercondylar furrow. Old scar is adhered to the low contact plate in the distal third.

Direct approach on the lower pole of the patella until the anterior tuberosity of the tibia. Removal of the medial third of the bone-tendon-bone graft, 10 mm wide, and bone segments approximately 2.5 cm. With a pinpoint guide in anatomic footprints, a 9-mm tunnel is made externally-internally into the femur, and a 10-mm tunnel is made in the medial face of the tibia using a tibial guide. The graft is passed through and fixed with 7 × 25 mm titanium screws in the femur and tibia, achieving the proper tension without any pinching after lateral femoral condyle bone margin plasty.

3D utility: the 3D reconstruction (see Figure, Supplemental Digital Content 2C, <http://links.lww.com/JG9/A8>) allowed us to visualize the incorrect tunnel placement from the first surgery. We then achieved excellent placement of the anteromedial band using an anterior tunnel rather than a distal tunnel. Visualization of the meshes from an internal perspective of the knee allowed us to see the location of the tunnels with regard to the anatomic footprints and permitted us to accurately plan the length and direction of new tunnels during the surgery. The real-scale 3D printed model of the knee helped

Figure 4



**A**, Lateral radiograph of patient E with Proteus syndrome. **B**, Photograph showing the lateral view of a 3D print of the foot with the screws from previous surgeries highlighted in red. **C**, Photograph showing the 3D virtual representation of the foot with a transparency factor that allowed the surgeon to visualize three screws.

the medical team and the patient understand the pathology better. Finally, the 3D model (see Figure, Supplemental Digital Content 2B,

<http://links.lww.com/JG9/A8>) was fundamental to obtain the necessary measurements and orientation for the surgical planning.



**Patient G**

Surgery type: foot.

Date of surgery (patient sex, age):  
January 26, 2016 (female, 61 years).

Preoperative diagnosis: patient with a flat left foot who underwent surgery in 2014 with arthrodesis (see Figure, Supplemental Digital Content 3A, <http://links.lww.com/JG9/A9>). The patient had persistent pain, and was found to have poor fusion of a triple arthrodesis with tibiotalar arthritis. The surgeon decided to perform realignment of the hindfoot in addition to a tibiotalar arthrodesis.

Surgery: osteotomy of the ankle and calcaneus.

Previous judgment: poor alignment of the hindfoot and previous tibiotalar arthrodesis that require surgery.

Surgical details: lateral approach, identification of the distal fibula and resection. Identification of the arthritic tibiotalar joint with necrotic talus and poorly fused subtalar with the talus valgus and laterally displaced. Temporary fixation with a Kirschner needle. Osteosynthesis removal of previous arthrodesis of the lateral column. Lateral calcaneal exostectomy and proper posterior apposition of the lateral arthrodesis plate (arthrex). Fixation to the proximal cortex and arthrodesis fixation with two screws. Tibiotalocalcaneal compression plantars and the fixation of the lateral plate to proximal and distal.

3D utility: the printed model (see Figure, Supplemental Digital Content 3B, <http://links.lww.com/JG9/A9>) allowed us to precisely define the location of the malformation. The virtual simulation of the surgery was a great help in decreasing the overall surgery time. Furthermore, given that the surgery was a complex procedure,

there were different points of view as to the best approach. The virtual model provided more information in terms of dimensionality; the surgeons were able to simulate the different procedures and finally reach an agreement as a team with regard to defining the approach.

### Quantitative Evaluation of 3D Print Models on Improvement of Surgical Planning

Each surgeon was asked to complete a questionnaire related to surgical and presurgical planning times (hours:minutes), bleeding volume (in milliliters), level of satisfaction with surgical outcome (Likert scale score from 1 to 4, unsatisfactory to very satisfactory), and physician-patient relationship in regard to the explanation of the pathology and surgery (Likert scale score from 1 to 3 [worsened, no change, improved]). These questions were to be answered in cases of surgeries in which 3D printed models were used and in similar procedures performed without the assistance of 3D technology (Table 1).

### Results

A decrease in surgical time was obtained in all cases when using 3D printed models because the surgeons were able to perform detailed surgical planning. The mean surgical time decreased by 42.5% (SD, 14.5%). Regarding the duration of surgical planning using 3D models, cases A and D (ie, spine surgery) the time decreased by an average of 80.0%, cases B (ie, skull surgery) and G (ie, foot surgery) increased by an average of 150%, and remained the same for cases C, E, and F.

The use of 3D printing models resulted decreased bleeding during surgery. An average decrease of 50.4% (SD, 35.4%) was obtained.

In patients A and G, the 3D model allowed the surgeon to change the strategy of the surgical approach, which in turn resulted in a decrease in the number of surgeries required and surgical aggressiveness.

Furthermore, in patients B and G, a virtual and physical simulation of surgery was performed using electric saws, which allowed the surgeon to practice the procedures that would be performed in the operating room on a scale model. With respect to the level of surgeon satisfaction in using 3D models in relation to the result of similar surgeries without the use of this technology, an increase in the mean score of 3 (range, 2.0 to 3.0; SD, 0.58) to 4 (all values, 4.0) was observed. Finally, surgeons agree that the doctor-patient relationship in terms of pathology explanation improved when using a 3D model (ie, surgeons answered level 3 in the last question in Table 1).

### Discussion

3D printing techniques have proved to be essential in the field of medicine, generating benefits not only for the patient but also for the team of surgeons. A multidisciplinary team of professionals using CT and MRI can create the segmentation, 3D mesh, and printed model. The intermediate processes (ie, segmentation, postprocessing of the mesh, and 3D visualization) are complex and semiautomatic and require several hours of work with high-level specialists, computer aided diagnosis management, and a medical imaging protocol that defines the necessary characteristics for an optimal 3D printed model.

The use of 3D printing technology allows the surgeon to develop presurgical planning with scale models, as a new paradigm of personalized medicine, providing a greater amount of information for the surgery, which results in a decrease in surgical time,



Table 1

Questionnaire About Surgical and Presurgical Planning Time, Bleeding Volume, Level of Satisfaction With Surgical Outcome, and Physician-Patient Relationship in Regard to the Explanation of the Pathology and Surgery								
Question	Answer	Patient A	Patient B	Patient C	Patient D	Patient E	Patient F	Patient G
Average duration of similar surgeries	Hour:minute, 0-24 hr	3:00	4:00	4:00	5:00	4:00	2:30	2:00
Duration of surgery with 3D printing	Hour:minute, 0-24 hr	2:15	2:00	1:45	2:30	1:50	2:00	1:10
Duration of surgical planning in similar surgeries	Hour:minute, 0-24 hr	0:45	1:00	0:15	1:00	1:00	1:00	1:00
Duration of surgical planning with 3D printing	Hour:minute, 0-24 hr	0:10	2:00	0:15	0:10	1:00	1:00	3:00
Estimated bleeding in similar surgeries	mL	300	500	300	1,100	500	300	500
Estimated bleeding in surgery with 3D printing	mL	50	300	300	700	400	50	50
Satisfaction of the result in similar surgeries	1 (dissatisfied)	—	—	—	—	—	—	—
	2 (medium)	—	—	2	—	—	—	—
	3 (satisfied)	3	3	—	—	3	3	3
	4 (very satisfied)	—	—	—	4	—	—	—
Satisfaction of the result in surgery with 3D impression	1 (dissatisfied)	—	—	—	—	—	—	—
	2 (medium)	—	—	—	—	—	—	—
	3 (satisfied)	—	—	—	—	—	—	—
	4 (very satisfied)	4	4	4	4	4	4	4
Physician-patient relationship in terms of explanation of pathology using 3D printing	1 (worse)	—	—	—	—	—	—	—
	2 (no change)	—	—	—	—	—	—	—
	3 (better)	3	3	3	3	3	3	3

less bleeding, fewer risks, decreased decision-making time, and a faster recovery time. With the development of models with 3D printers, it is possible to have a scale model of the object under study, for example, bone parts (ie, skull, knee, foot, and vertebrae) and soft tissues (ie, heart, brain, and kidney). Moreover, this technique allows the surgeon to provide a clearer explanation to the family and other physicians of the surgical procedures that will be performed on the patient. However, because of the high cost of 3D printers and materials, and the need for specialized professionals who can manage the images and create these models, it is still not a technique that has been widely adopted in many countries and medical centers.<sup>10</sup>

Some of the limitations of 3D printing (in particular, using Fused Deposition Modeling with acrylonitrile butadiene

styrene) include the lack of ability to visualize anything inside the object; for example, for patient F, the previous surgical canals could only be observed in the exterior part of the knee piece. To be able to visualize the canals, the only option, in this case, was to use different software that allowed the surgeon to observe the meshes from the inside. Other limitations arise from the incompatibility of the materials to be implanted in the human body. To create implants, specific materials approved by the FDA are required, and therefore, it is necessary to investigate the body's reaction to these materials and prove that they are safe and do not cause any adverse effects. The FDA is currently working on a list of 3D printing materials that may be compatible with the human body.<sup>11</sup>

The preparation time required for creating the models is one of the most

notable limitations of the 3D printing procedure. The reconstruction of complex virtual models cannot be automated and must be performed by multidisciplinary teams that include surgeons, radiologists, and engineers to obtain high-quality models. This multidisciplinary collaboration is fundamental for an accurate model. It is important for the surgical planning that the 3D model has a high level of accuracy with respect to the real anatomy. One of the important factors to be able to achieve this is to obtain high-resolution images without any artifacts. The resolution of the images as well as the presence of artifacts (such as those caused by metal implants) can affect the accuracy of the model.

With regard to future advances in technology, these limitations should

decrease, with shorter printing times, greater accuracy of the models, a greater amount of printing materials destined for implants, improved printer resolution, and advanced modeling techniques. In a recent study of 158 patients,<sup>12</sup> molds (n = 10), implants (n = 15), surgical guides (n = 40), and anatomic models (n = 113) were created using 3D printers; the greatest benefits that were reported were the following: better surgical planning (n = 40; 48.7%), greater precision in the processes (n = 53; 33.5%), and a decrease in surgical time (n = 52; 32.9%).

Based on the questionnaire (Table 1), there was a decrease in the duration of surgery and bleeding (>29%). However, in some of the patients, the planning time increased when using 3D printing. For example, in patient B, tools were used to cut the printed model to plan the surgical approach, which resulted in the increased surgical planning time. In complex cases, the explanation of the pathology to the patients may not be clear when unaided by a 3D model. When using the printed models, surgeons can explain the pathology and the surgical procedure to the patient.

## Conclusions

The anatomical models created with 3D printing technology are essential for good surgical planning and surgical simulation in some cases (patients B and G). These models are even more important for complex cases in which additional information is required that only 3D models can provide. By having clarity with regard to the problem, thanks to the additional information, a better intervention strategy can be developed with many benefits for the patient and a decrease in risks, procedure times, and recovery times.

## References

- Garekar S, Bharati A, Chokhandre M, et al: Clinical application and multidisciplinary assessment of three dimensional printing in double outlet right ventricle with remote ventricular septal defect. *World J Pediatr Congenit Heart Surg* 2016;7:344-350.
- Jastifer JR, Gustafson PA: Three-dimensional printing and surgical simulation for preoperative planning of deformity correction in foot and ankle surgery. *J Foot Ankle Surg* 2017;56:191-195.
- PwC: *3D Printing and the New Shape of Industrial Manufacturing*. Chart pack, June 2014. <https://www.pwc.com/us/en/industries/industrial-products/library/3d-printing.html>. Accessed January 9, 2017.
- Davis L, Hawkinson E: Board 511-technology innovations abstract 3D printing: A new frontier in simulation (submission #514). *Simul Healthc* 2013;8:614.
- Mpofu TP, Mawere C, Mukosera M: The impact and application of 3D printing technology. *Int J Sci Res* 2014;3:2148-2152.
- Chae MP, Lin F, Spychal RT, Hunter-Smith DJ, Rozen WM: 3D-Printed haptic "Reverse" models for preoperative planning in soft tissue reconstruction: A case report. *Microsurgery* 2015;35:148-153.
- AlAli AB, Griffin MF, Butler PE: Three-dimensional printing surgical applications. *Eplasty* 2015;15:e37.
- Yushkevich PA, Piven J, Hazlett HC, et al: User-guided 3D active contour segmentation of anatomical structures: Significantly improved efficiency and reliability. *Neuroimage* 2006;31:1116-1128.
- Cignoni P, Callieri M, Corsini M, Dellepiane M, Ganovelli F, Ranzuglia G: MeshLab: An open-source mesh processing tool. Sixth Eurographics Italian Chapter Conference, 2008, pp 129-136. <http://vcg.isti.cnr.it/Publications/2008/CCCDGR08>.
- Rankin TM, Giovinco NA, Cucher DJ, Watts G, Hurwitz B, Armstrong DG: Three-dimensional printing surgical instruments: Are we there yet? *J Surg Res* 2014;189:193-197.
- Hibino N: Three dimensional printing applications in surgery for congenital heart disease. *World J Pediatr Congenit Heart Surg* 2016;7:351-352.
- Martelli N, Serrano C, van den Brink H, et al: Advantages and disadvantages of 3-dimensional printing in surgery: A systematic review. *Surgery* 2016;159: 1485-1500.